

## Original Article

# Unveiling the Clinicopathological and Molecular Spectrum of Fanconi Anaemia: Insights from a Single-Centre Experience

Saima Siddiqui\*<sup>1</sup> MBBS, FCPS, Ikram din Ujjan<sup>2</sup> PhD, Shariq Ahmed<sup>1</sup> PhD, Danish Zahid<sup>1</sup> PhD, Safia Mehmood khan<sup>1</sup> Pharm.D, Mphil, Affaf Sheikh<sup>1</sup> MBA, Ali Waryah<sup>2</sup> PhD.

<sup>1</sup> National Institute of Blood diseases and Bone Marrow Transplantation, PECHS campus, Pakistan

<sup>2</sup> Liaquat University of Medical and Health Sciences (LUMHS), Deh Soun Valhar., Jamshoro, Sindh, Pakistan

Received: March 10, 2025;  
Accepted: November 18, 2025

\*Corresponding Author: Saima Siddiqui, National Institute of Blood diseases and Bone Marrow Transplantation, PECHS campus. Email: saimee\_80@yahoo.com. ORCID ID: 0000-0001-5178-937X.

## Abstract

**Background:** Fanconi anaemia (FA) is the most common cause of constitutional bone marrow failure. The pathophysiology of this disease is highly complex and still unclear. It is caused by a mutation/pathogenic variant in any of the 22 complementation groups that work together in the DNA damage repair mechanism. Approximately three-fourths of FA cases are due to defects in the FANCA gene. This study investigates the molecular and clinicopathological profiles of FA patients.

**Materials and Methods:** This prospective observational study screened 780 aplastic anaemia patients using chromosomal breakage analysis, and the results were positive for 60 patients, therefore labeled as FA. Baseline biodata and clinical and laboratory parameters were recorded via a questionnaire. In this study, Samples from the first 50 patients were screened for c.378803790delTCT through PCR RFLP, which revealed its presence in one patient. Ten additional samples were also screened via next-generation sequencing (NGS) for broader genetic analysis.

**Results:** The median age of the patients was 11.5 years (IQR 5 years), with the majority (68%) of the participants being male. Growth retardation and pancytopenia were present in 98.3% and 95% patients, respectively. A total of 20 variants were detected (2 via RFLP and 18 via NGS). Seventeen were pathogenic variants, of which 16 (80%) affected FANCA and 20% affected FANCG. Twelve variants (74%) in FANCA were deletions. c.3788-3790delTCT was detected in 3 out of 60 patients (1 through RFLP and the other 2 through NGS).

**Conclusion:** FA is a clinically and genetically heterogeneous disease. Patients presenting with cytopenia combined with growth retardation and somatic abnormalities should be suspected of having FA. Genetic diagnosis is necessary for confirmation. NGS can aid in the diagnosis and subtyping of patients in whom targeted/hotspot mutations are unknown.

**Keywords:** Fanconi anaemia, FANCA, Inherited bone marrow failure, Next-generation sequencing.



## Introduction

Fanconi anaemia (FA) was first described in 1927 by Guidino Fanconi in 3 brothers with pancytopenia and congenital anomalies (1). It is inherited in an autosomal recessive manner in the majority of cases except for mutations in FANCB and FANCR, which are X-linked and autosomal dominant, respectively (2). The worldwide incidence of FA is 1/350,000 live births (3). However, some populations, such as Ashkenazi Jews and Afrikaners, who established new colonies after migrating from their parent country (founder effects), have an increased frequency (4, 5). The pathophysiology of FA is highly complex and not fully understood. Mutations in any of the 22 FA complementation groups, most commonly FA, lead to impaired DNA repair. (6). All these genes work together to sense, signal, and repair DNA damage caused by interstrand DNA crosslinks (ICL). When DNA damage occurs, eight upstream FA proteins, namely, FANCA/B/C/E/F/G/L/M, form a complex known as the FA core complex (CC), which causes monoubiquitination of FANCD2 and FANCI. This monoubiquitinated FANCD2 is recruited to chromatin, where it identifies stalled replication forks and participates in DNA repair (7, 8).

Mutations in any of these genes hinder the formation of the core complex, thereby impairing the DNA repair mechanism. To counter this type of DNA damage, FA cells initiate an error-prone DNA repair pathway that leads to the formation of structurally abnormal chromosomes, including radial figures. This failure to repair DNA damage leads to chromosomal instability, bone marrow failure, susceptibility to malignancy, and multiple congenital anomalies(8). Approximately three-quarters of FA cases are due to mutations in the FANCA gene, which is located on the long arm of chromosome 16 and is a large and polymorphic gene with a total of 43 exons. More than 100 variants, including single nucleotide substitutions, small and large deletions, and insertions, have been reported in this gene, with a detection rate of 30–70% of FA cases(9).

Owing to chromosomal instability, cells from Fanconi anaemia patients either spontaneously or when exposed to ICL agents, e.g., mitomycin C (MMC) or diepoxybutane (DEB), exhibit multiple breaks in chromosomes. This is the basis of the diagnostic MMC test in this disease and is considered the gold standard diagnostic test. However, it can produce false-positive results, as in Nijmegen

breakage or Bloom's syndrome, or false-negative results, as in cases of mosaicism (10–30% of cases). Therefore, the definitive diagnosis is based on genetic testing through different techniques (7).

Phenotypically, FA is very heterogeneous and ranges from apparently normal individuals to individuals with severe pancytopenia, short stature, and congenital anomalies. This variation makes the diagnosis of FA difficult in the 30% of patients who are asymptomatic and lack pathognomonic features (10).

There is limited data on FA in Pakistan, where consanguinity may increase prevalence (11). There is a paucity of literature regarding the phenotypic presentation, ethnic distribution, and genetic studies of this disease in understudy population.

The present study aimed to identify the genetic variants of FA patients and their clinicopathological features in Pakistan. It will also help families in prenatal diagnosis during subsequent pregnancies and genetic screening of family members.

Larger studies are warranted to establish the true incidence of FA in Pakistan and to evaluate inherited bone marrow failure syndromes (IBMFs) more broadly, including in patients presenting with early-onset malignancies and congenital anomalies. Such strategies will enable earlier detection, improved management, and prevention of therapy-related toxicities in FA patients.

## Material and Methods

### Study Population

After approval from the institutional review board (IRB#: NIBD/RD-169/18-2014) and both verbal and written informed consent of patients or guardians (for patients <18 years), this prospective observational study was carried out from 2014 to 2020. A total of 780 patients with aplastic anaemia (diagnosed as per Camitta criteria) who presented as either outpatients or inpatients at the National Institute of Blood Diseases and Bone Marrow Transplantation were recruited for the study. Sixty of 780 patients were diagnosed with FA based on chromosomal breakage analysis. Patient demographic data, family history, consanguinity, ethnicity, and a detailed physical examination were recorded in the questionnaire. Initially, fifty patients were screened through restriction fragment length polymorphism (RFLP) for c.3788-

3790delTCT (as this is the most common mutation reported worldwide and in Pakistan), whereas ten samples were subsequently analyzed through next-generation sequencing (NGS) using the TruSight inherited panel, as c.3788-3790del TCT was detected in only 1/50 samples via RFLP. Therefore, to screen a broader genetic area, an NGS TruSight panel was utilized. Whole exome sequencing (WES) could be another option; however, it was not an available or financially possible option for this study. Variants were classified as pathogenic, likely pathogenic, variant of unknown significance (VUS), likely benign, or benign in accordance of the ACMG criteria 2015, using 28 types of evidence that includes, Very Strong (PVS1), Strong (PS1–PS4), Moderate (PM1–PM6), Supporting (PP1–PP5), and benign evidence (BS, BP), Loss-of-function mutations (PVS1), functional evidence (PS3), rarity in population databases (PM2), computational predictions (PM4/PP3), and phenotype–genotype correlation (PP4).

#### *DNA extraction*

Genomic DNA was isolated from 3 cc of peripheral blood taken in EDTA by using a QIAamp DNA Blood Mini Kit (Qiagen, Hilden, Germany) according to the manufacturer's protocol. The quality of the DNA was assessed via 2% agarose gel electrophoresis and quantified via a Qubit DNA HS Assay Kit (Invitrogen, Thermo Fisher Scientific, United States).

#### *Restriction fragment length polymorphism (RFLP)*

A restriction fragment analysis assay was carried out to modify the mismatch PCR assay, which was performed for the c.3788\_3790del TCT in only 50 patients. A reverse 26 bp primer was designed to abolish the restriction MboII site in the mutant allele, and a restriction cut at the MboII site was observed in the normal alleles. PCR amplification was performed with a flanked exon 38 forward primer with a designed modified mismatch primer. Three units of MboII enzyme were added directly to the PCR product, which was subsequently incubated for 1 hour at 37 °C. The digested PCR products were separated on 2.5% agarose gels.

#### *Next-generation sequencing*

To assess the genetic characterization of FA, the TruSight One Sequencing Panel (Illumina, San Diego, CA, United States) was used. It targets 4811 genes, including FANCA and other genes associated with FA. The panel consists of 62,000 amplicons (length range: 225–275 bp) and covers a 12 Mb genomic region of ~250 bp fragment lengths.

#### *Bioinformatics analysis*

Data analysis followed the conventional pipeline (12). First, the quality of the raw data was checked via FastQC(13). All the clean data were subsequently aligned to the human reference genome hg19 (UCSC) via the Burrows–Wheeler Aligner (BWA-MEM) algorithm. Conversion of sequence alignment files (SAM) into binary alignment files (BAM) was executed via SAMtools v 0.1.18 (14), and marked duplicates were removed via PICARD Tools (v2.5.0)(15). Base quality score re-calibration (BQSR) and accurate variant calling were performed following the recommended pipeline, the Best Practices Genome Analysis Toolkit (GATK) (16). The identified SNPs and indel variants were annotated, and predictions were carried out via the SnpEff tool (17) on the basis of gene-based methods according to protein coding changes and filter-based methods. The mutation allele frequency (MAF) was <1% in the 1000 Genomes Project, as the variants are rare. The pathogenicity of non-synonymous variants was assessed with Polyphen2, SIFT, and CADD (18).

#### *Statistical analysis*

The analysis was performed using SPSS version 24.0. The normality of the data was evaluated via the Shapiro–Wilk test. The categorical variables are presented as frequencies and percentages, while the continuous variables are presented as medians (interquartile ranges/ IQRs).

## **Results**

### *Clinicopathological features*

Among the 60 FA patients, males composed the predominant population (n=40; 66.7%). The median age was 11.5 years (IQR: 5 years and range 3-35 years). Ninety-five percent (n=57) of patients presented with bone marrow failure, and one patient had acute myeloid leukaemia. Two out of

60 patients (1.6%) were diagnosed during the workup for short stature, and cytopenias were incidental findings. Family history was positive in 40% (n=24) of patients, whereas parental consanguinity was present in 87% (n=52) of patients. The ethnic distribution of the study population is displayed in Figure I, with the most frequent being Urdu-speaking, followed by Sindhi and Pashto speakers. The frequencies of haematological and phenotypic abnormalities in all 60 patients are shown in Table I.

Table II shows the clinical features and genetic results of those patients in whom pathogenic variants were detected. At the time of analysis, N=16 (26.6%) of the patients had died, whereas 16.6% (n=10) of the patients were lost to follow-up. Fifteen patients (25.0%) underwent bone marrow transplantation, of whom 47% (n=12) were alive to date, while one patient succumbed to squamous cell carcinoma of the oral cavity 10

years after transplantation.

Figure 1 shows the ethnic distribution of Fanconi anaemia patients.

Figure II illustrates the phenotypic abnormalities. Figure II A represents a radial ray anomaly with an absent thumb; Figure II B shows Café au lait spots on the hands.

#### *Genetic Results*

A total of 20 variants were detected. Two variants were detected in the initial 50 samples screened by RFLP. NGS detected 18 variants in 9 out of 10 samples, whereas no variant was detected in one sample. A total of 17 out of 20 variants were pathogenic, while the remaining variants were VUSs, as shown in Table II. Among the pathogenic variants, 16 (80%) belonged to FANCA, whereas 1 (20%) belonged to FANCG. Twelve (75%) FANCA variants were deletions, whereas two were frame shifts and duplications. c.3788-3790delTCT was detected in 3 patients.

*Table I: Clinico-pathological features in the study participants*

Parameters	N (%)
Short stature	59 (98.3)
Underweight	58 (96.6)
Hematological abnormalities	57 (95.0)
Facial features	36 (60)
Microphthalmia	34 (56.6)
Skin changes	25 (41.6)
Skeletal abnormalities	16 (26.6)
Renal abnormalities	14 (23.3)
Solid tumor	01 (1.6)

*Table II: Phenotypic and genetic results of patients*

	Age (y)	Sex	Cytop	Sk abn	Cafe au lait	Mic	FF	Variant	V Int	Zyg	Gene	rs# / ref
*1.	8	M	+	-	+	+	+	c.3788-3790delTCT	P	Hm	FANCA	397507553/[36]
**2.	10	M	+	-	+	+	+	c.3788-3790delTCT	P	Hm	FANCA	397507553/[36]
**3.	12	M	+	-	+	-	+	Deletion of Exon 6	P	Hm	FANCA	[25]
**4.	2	M	+	-	+	-	-	c.1077-2A>G c.1076+3_1076+7del	P V	Ht Ht	FANCG FANCG	769547477/[37] 780410457/[38]
**5.	7	M	+	-	-	+	+	c.3239+1dup	P	Hm	FANCA	766989857/[39,40]
**6.	6	M	+	-	-	-	-	Deletion Exons 4-7	P	Hm	FANCA	[25]
**7.	7	M	+	-	+	+	+	Deletion Exons 4-7 RUNX1	P	Hm	FANCA	[25]
**8.	13	M	+	+	+	+	+	c.1814-1815del	P	Hm	FANCA	759899153/[40]
**9.	13	M	+	-	+	+	-	c.1278+3_1278+6del c.146A>G	V V	Ht Ht	FANCD2 FANCC	369823368/[42] rs761845692
**10.	6	M	+	+	+	+	+	---				
**11.	9	M	+	-	+	+	+	c.3788-3790delTCT	P	Hm	FANCA	397507553/[36]

M: male, Cytop: cytopenias, Sk Abn: skeletal abnormality, Mic: microphthalmia; FF: Fanconi facies, V Int: variant interpretation, Z: Zygosity, rs #: rs number, ref: reference number

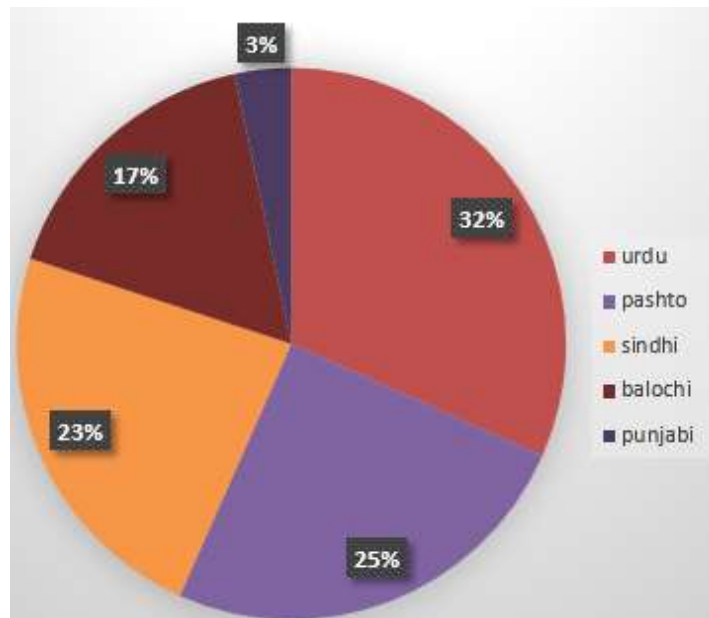


Figure 1. The ethnic distribution of Fanconi anaemia patients

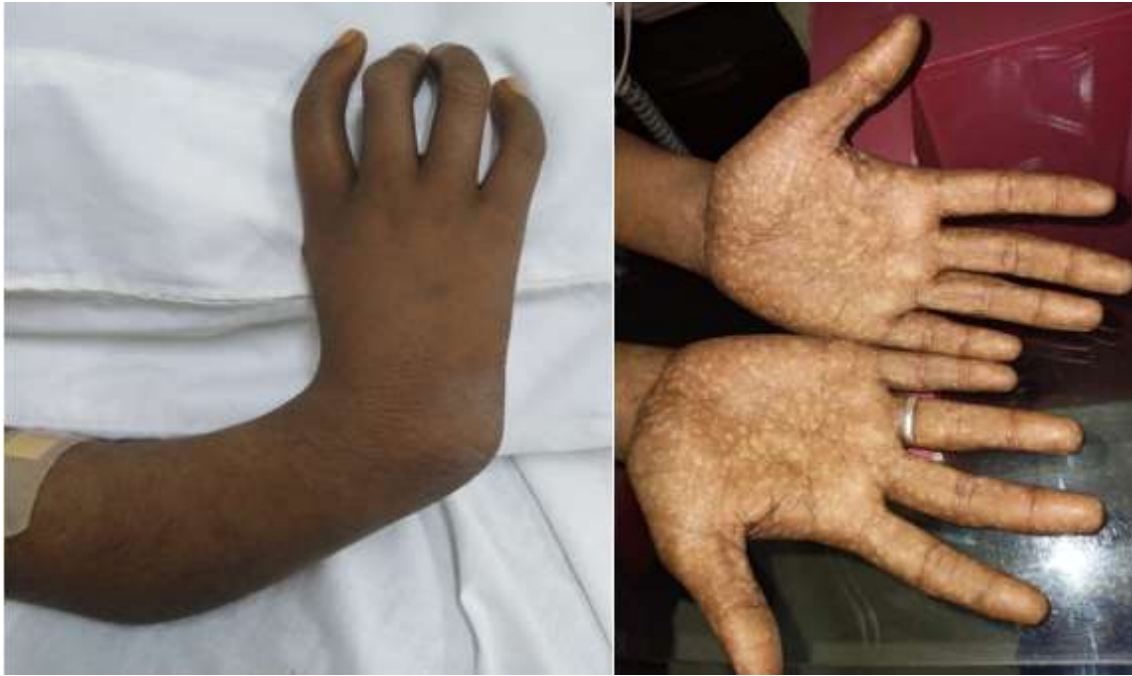

Figure 2. The Phenotypic abnormalities. Left figure represents a radial ray anomaly with an absent thumb; Right figure shows Café au lait spots on the hands

## Discussion

FA is a complex disorder both phenotypically and genetically. Various pathogenic variants have been detected in the 22 genes described above, among which approximately 60% of the mutations occur in the complementation group FANCA, whereas 25–30% occur in FANCC and FANCG (19).

FA is the most common cause of IBMFS. These patients have normal blood counts at birth; however, the majority, by a median of 7 years of age, develop cytopenias, and by the fourth decade, 98% of patients develop bone marrow failure. The median age of patients was 11.5 years, and 98.3% of them presented with AA. The exact pathophysiology of the development of bone marrow failure in FA is still unknown. However, these patients have extremely low CD34 counts, which favour the hypothesis that prenatal defects in stem cells progressively lead to marrow failure and cytopenias (20). Recent studies have highlighted the role of Tp53/p21 in the development of bone marrow failure. The faulty DNA repair mechanism in FA patients leads to the activation of Tp53, which in turn leads to cell cycle arrest, increased apoptosis, and hence progressive bone marrow failure (21).

Somatic defects are among the features that indicate the presence of underlying FA. In this

study, 26% of patients had skeletal defects, mainly involving the thumb and radius. According to the literature, 50–70% of patients with FA have single or multiple skeletal defects, approximately 2/3rd of which are in the upper extremities. These include radial ray defects, thumb hypoplasia, hip dislocations, and scoliosis (10, 22).

The presence of typical craniofacial features strongly favours FA. The typical Fanconi facies includes facial changes, such as delicate triangular faces, microphthalmia, microcephaly, low-set ears, and small mouths and chins (23). These abnormalities have been reported in up to 25% of cases, and isolated microphthalmia has been reported in 38% of cases (22). Sixty-one percent of total patients had these typical facial features, whereas 57% of patients had microphthalmia. This is in accordance with an Indian study in which half of the patients had microphthalmia (24).

Skin pigmentation changes are another feature of FA that is described in approximately 60% of cases. These include café au lait spots and hyperpigmented macules, usually on the trunk and limbs (25). In this study, 43% of patients exhibited these skin changes.

Renal abnormalities that are well described in the literature were present in 23% of the study population (22). These changes are usually identified incidentally during radiological studies and include structural changes (the absence of one kidney,

hypoplastic and/or malformed kidneys that are usually horseshoe shaped, ectopic kidneys, and double ureters) (26). Approximately 1/3rd of FA patients have structural renal abnormalities (22).

The majority (>80%) of FA patients are growth retarded (underweight and short stature). This is due to multiple factors, e.g., growth hormone deficiency, abnormal glucose metabolism, hypogonadism, or hypothyroidism (27). In this study, 98% of patients had short stature, whereas Rose et al reported that approximately 60% of children and 58% of adults had short stature (28). This finding warrants early endocrine workup and subsequent management of these patients.

Hematopoietic stem cell transplant (HSCT) is the curative option for bone marrow failure in these patients and improves survival (29). Therefore, 16/60 (26%) patients underwent HSCT from a fully matched sibling donor. Among them, 43% of patients survived and remained well 5 years post-transplant. However, one of the patients developed squamous cell carcinoma (SCC) of the left cheek 10 years after HSCT and died during treatment. According to the literature, the risk of SCC of the head and neck increases 4.4-fold after bone marrow transplantation (30). It has also been reported that increased survival in these patients is associated with increased potential for clonal evolution; hence, there is an increased risk of malignancies in those who live longer. The risk of solid tumors also increases after HSCT, especially in patients who experience chronic graft-versus-host disease (GVHD) (31).

The prevalence of FA has not been studied in Pakistan. Wali et al reported 16.6% FA cases among 90 cases of AA, whereas Siddiqui et al reported 33.7% (32, 33). In the current group of patients with aplastic anaemia, 7.69% (60/780) of patients had FA. Its frequency may be greater because many patients remain undiagnosed and many are unregistered.

#### *Genotypic findings*

FA has a diverse genetic spectrum, with two common variants reported across different ethnic groups. These include c.3788-3790delTCT (exon 38) and c.1115\_1118delTTGG (exon 13) of FANCA. This exon 38 variant has also been identified in Pakistani families (8), prompting us to initially screen 50 samples for the c.3788-3790delTCT mutation. However, it was detected in

only one sample. Therefore, an additional 10 randomly selected samples were screened through the NGS TruSight panel to analyse a broader genetic area.

A total of 20 variants were detected (2 by RFLP and the rest through NGS). Among the 20 variants, 17 were pathogenic. The majority (16) of the pathogenic variants were FANCA, whereas 1 was FANCG, and 75% of the FANCA pathogenic variants were deletions. According to the literature, 60–70% of cases of FA are attributed to mutations in the FANCA gene, with approximately 40% of these mutations being deletions (9). The increased prevalence of deletions in the FANCA gene is believed to be linked to the numerous Alu repeats present within the gene (9, 34). Deletions in FANCA are particularly frequent, partly due to the gene's large size—approximately 170 kilobases—and its coding region's susceptibility to rearrangements and deletions originating from genomic instability(9). The most commonly reported deletion across various ethnic groups is c.3788-3790delTCT. In the present study, it was detected in three patients. It is a pathogenic variant reported in 10–20% of patients, including Pakistani individuals (35). The highest frequency of this variant was reported from La Palma Island, Spain, at approximately 80%. It is a small deletion of 3 nucleotides from the mRNA of FANCA, leading to the deletion of one amino acid residue from the protein. All 3 patients were growth retarded and presented Fanconi facies, microphthalmia, and café au lait spots; however, no other somatic abnormalities were detected. (35).

Homozygous deletion of exon 6 of FANCA was detected in one patient. Deletion of exon 6 is out of frame, which leads to a premature stop signal, resulting in the absence or disruption of the protein (9). This variant has been reported in the Indian population (2).

In another patient, two variants were detected in FANCG. The first variant was c.1077 2A>G, also known as IVS8-2A>G, which affects the splice site in FANCG, resulting in the absence or disruption of the protein product (36). It is associated with an increased frequency of congenital malformations. In this study, the patient had congenital duodenal atresia, an undescended testis, and an umbilical hernia. This variant has been described in Portuguese Brazilians but has not been reported in Pakistan. The second variant detected in this individual was

c.1076+3\_1076+7del. This is a very rare variant that has been reported in 1 out of 246250 alleles. It is predicted that this variant weakens the donor splice site. However, currently, this variant has been labeled a VUS by Clinvar public database (NCBI) (37).

A sequence change of c.3239+1dup of FANCA was detected in the homozygous state in a patient who presented with celiac disease and short stature. However, he had typical Fanconi facies, microphthalmia, café au lait spots, and short stature. This sequence change affects a donor splice site in intron 32 of the FANCA gene and results in an absent or disrupted protein product (38, 39). This variant is labelled pathogenic.

Homozygous deletion of exons 4-7 in the FANCA gene was identified in two patients, each of whom presented with distinct phenotypic features. The deletion of these exons disrupts RNA splicing, resulting in the absence of the protein product (2). One patient exhibited only growth retardation, with no other phenotypic abnormalities, although the presence of cytopenia and a positive family history indicated a potential diagnosis of Fanconi anaemia (FA). In contrast, the second patient presented with a range of symptoms, including Fanconi facies, growth retardation, microphthalmia, café au lait spots, and acute myeloid leukaemia. In this patient, in addition to the deletion of exons 4-7 in FANCA, the deletion of exons 6-7 of the RUNX1 gene was also discovered. RUNX1 deletions are frequently observed as somatic mutations in both FA patients and various haematological malignancies. Compared with de novo or acquired forms of acute myeloid leukaemia/myelodysplastic syndrome AML/MDS, this mutation is particularly prevalent in AML/MDS secondary to constitutional bone marrow failure. In the case of FA, this mutation is associated with resistant or refractory disease in AML/MDS, differing from acquired AML/MDS (40). Notably, under-study patients exhibited refractory disease that did not respond to induction chemotherapy.

Homozygous c.1814\_1815del was detected in one patient who had cytopenia along with microphthalmia, skeletal abnormalities, café au lait spots, and typical facies. This is a pathogenic variant that leads to a frame shift and results in a disrupted or absent protein (39).

c.1278+3\_1278+6del in FANCD2 was detected along with c.146A>G in FANCC in a patient with cytopenia, café au lait, and microphthalmia. However, both of these variants are designated as VUSs by ClinVar(public database) according to the ACMG criteria of 2015 (41).

The current study had certain limitations. Any relationship between genotype and phenotype could not be established because the molecular results of only a limited number of patients were available. Financial constraints and difficulty in resampling patients, either because of high mortality or loss to follow-up, were the main attributes for the performance of genetic testing in a small subset of patients. c.3788-3790del TCT was screened in the initial 50 samples. However, it was identified in only 1/50 of the samples. Therefore, an additional 10 samples were screened randomly through NGS to analyse a much broader area. WES was not a feasible option because of its inaccessibility and high cost. Furthermore, the genetic results of this study are not representative of the entire Pakistani population, and much larger genetic studies are needed in the same population.

## Conclusion

FA is a heterogeneous disease both clinically and genetically. NGS, although an expensive technique, can be helpful in the genotypic evaluation of such diseases in which targeted mutations are not known, and multiple genes are involved. This comprehensive analysis of FA patients evaluated at NIBD hospital underscores the complex and heterogeneous nature of this rare disorder. The insights gained from this study enhance the understanding of the clinical manifestations and disease progression while also highlighting the importance of molecular diagnostics in guiding personalized treatment approaches. By elucidating the genetic basis and associated complications, this study aims to contribute to the growing body of knowledge that will inform future research and improve the management of Fanconi anaemia. It is concluded that continued collaboration and data sharing within the clinical research community are crucial to advance care and outcomes for individuals affected by this condition by counselling families about the role of prenatal testing and genetic

screening of siblings.

### Availability of Data

Available upon reasonable request from the authors.

### Ethical Considerations

This study received ethical approval from IRB#: NIBD/RD-169/18-2014. Informed written consent was obtained from the participants/guardians. Confidentiality was ensured, and no identifiable data were collected. All procedures adhered to institutional and national ethical standards for human research.

### Acknowledgements

I would like to express my sincere gratitude to Dr. Tahir Shamsi, my mentor, who has always been a big support and has provided guidance at every step in this and every project throughout my career.

### Authors' Contributions

S.S: literature review, conceptualization, data collection

I.U: critical analysis

Shariq Ahmed: critical review, interpretation of data

D.Z: data acquisition

S.M: drafting

A.Sh: data analysis

W.A : critical review and final approval.

### Conflict of Interest

The authors declare that they have no conflicts of interest related to this manuscript.

### Funding

The authors have no relevant financial or nonfinancial interests to disclose.

### References

1. Fanconi G. Familiare infantile perniciosartige Anämia (pernicioses Blutbild und Konstitution). *Jahrb Kinderheilkd* 1927; 117:257-280.
2. Moreno OM, Paredes AC, Suarez-

Obando F, Rojas A. An update on Fanconi anemia: Clinical, cytogenetic and molecular approaches. *Biomed Rep* 2021;15(3):74-79.

3. Hoover A, Turcotte LM, Phelan R, Barbus C, Rayannavar A, Miller BS, et al. Longitudinal clinical manifestations of Fanconi anemia: A systematized review. *Blood Rev* 2024;101225-1012230.

4. Steinberg-Shemer O, Goldberg TA, Yacobovich J, Levin C, Koren A, Revel-Vilk S, et al. Characterization and genotype-phenotype correlation of patients with Fanconi anemia in a multi-ethnic population. *Haematologica* 2019;105(7):1825-1829.

5. Stones D. Fanconi anaemia: A perspective on phenotype, investigations and outcomes from central South Africa. *S Afr J Child Health* 2019;13(4):180-186.

6. Peake JD, Noguchi E. Fanconi anemia: current insights regarding epidemiology, cancer, and DNA repair. *Hum Genet* 2022;141(12):1811-1836.

7. Tan W, Deans AJ. The ubiquitination machinery of the Fanconi Anemia DNA repair pathway. *Prog Biophys Mol Biol* 2021; 163:5-13.

8. Chan SH, Ni Y, Li S-T, Teo JX, Ishak NDB, Lim WK, Ngeow J. Spectrum of germline mutations within fanconi anemia-associated genes across populations of varying ancestry. *JNCI Cancer Spectr* 2021;5(1): 117-119.

9. Mosaad R, El-Kamah G, Eid M, Amr K. DNA phenotyping and mapping intragenic deletion mutations in Fanconi anemia: Patterns and diagnostic inferences. *J Genet Eng Biotechnol* 2024;22(4):100435-100439.

10. Altintas B, Giri N, McReynolds LJ, Best A, Alter BP. Genotype-phenotype and outcome associations in patients with Fanconi anemia: the National Cancer Institute Cohort. *Haematologica* 2022;108(1): 69:1-9.

11. Bashir S, Nazir S. Thirty years of consanguineous marriages in Pakistan. *NUST j. soc. sci. humanit* 2022;8(3):17-32.

12. Lek M, Karczewski KJ, Minikel EV, Samocha KE, Banks E, Fennell T, et al. Analysis of protein-coding genetic variation in 60,706 humans. *Nature* 2016;536(7616):285-291.

13. Andrews S. Babraham Bioinformatics-

FastQC A Quality Control tool for High Throughput Sequence Data. *Babraham Bioinformatics* 2010;2-10.

14. Li H, Durbin R. Fast and accurate short read alignment with Burrows–Wheeler transform. *Bioinformatics* 2009;25(14):1754-1760.

15. Li H, Handsaker B, Wysoker A, Fennell T, Ruan J, Homer N, et al. The sequence alignment/map format and SAMtools. *Bioinformatics* 2009;25(16):2078-2079.

16. Hao Z, Liang X, Li G. Quality control and preprocessing of sequencing reads. *BIO-PROTOCOL* 2022; 12:13-18.

17. DePristo MA, Banks E, Poplin R, Garimella KV, Maguire JR, Hartl C, et al. A framework for variation discovery and genotyping using next-generation DNA sequencing data. *Nat Genet* 2011;43(5):491-498.

18. Cingolani P, Platts A, Wang le L, Coon M, Nguyen T, Wang L, Land SJ, Lu X, Ruden DM. A program for annotating and predicting the effects of single nucleotide polymorphisms, SnpEff: SNPs in the genome of *Drosophila melanogaster* strain Fly (Austin) 2012 ;6(2):80-92.

19. Sevilla J, Navarro S, Rio P, Sánchez-Domínguez R, Zubizaray J, Gálvez E, et al. Improved collection of hematopoietic stem cells and progenitors from Fanconi anemia patients for gene therapy purposes. *Mol Ther Methods Clin Dev* 2021; 22:66-75.

20. Ito E. Bone marrow failure and TP53 activating mutations. [Rinsho Ketsueki] *Jpn j. Clin Hematol* 2022;63(9):1115-1125.

21. Mahmood R, Mahmood A, Khan SA, Jaffar R. An experience with 124 cases of fanconi anemia: clinical spectrum, hematological parameters and chromosomal breakage analysis. *Am. J. Blood Res* 2021;11(5):498-500.

22. Rageul J, Kim H. Fanconi anemia and the underlying causes of genomic instability. *Environ Mol Mutagen* 2020;61(7):693-708.

23. de Castro Avila LF, Martins WD, Cândido L, Ignácio SA, Bonfim CMS, de Oliveira Ribas M. A study of facial pattern in patients with fanconi anemia. *CPCJ*

2014;51(1):83-89.

24. Solanki A, Mohanty P, Shukla P, Rao A, Ghosh K, Vundinti BR. FANCA gene mutations with 8 novel molecular changes in Indian Fanconi anemia patients. *PLoS One* 2016;11(1): e0147016-e0147019.

25. Barbus C, Rayannavar A, Miller BS, Jenkins MJ, Addo OY, Rayes A, et al. Development of specific growth charts for children with Fanconi anemia. *Am.J. Med. Genet* 2024;194(7): e63554-e63559.

26. Iram SI, Bano S, Aftab I, Amar A. Clinico-hematological Characterization of Pakistani Fanconi anemia patients. *JHSCR* 2021;1(2):79-83.

27. Fink O, Even- Or E, Avni B, Grisariu S, Zaidman I, Schejter YD, et al. Two decades of stem cell transplantation in patients with Fanconi anemia: Analysis of factors affecting transplant outcomes. *Clin Transplant* 2023; 37(1): e14835-e14839.

28. Dufour C, Pierri F. Modern management of Fanconi anemia. *Hematology*. 2022;2022(1):649-657.

29. Lum SH, Eikema D-J, Piepenbroek B, Wynn RF, Samarasinghe S, Dalissier A, et al. Outcomes of hematopoietic stem cell transplantation in 813 pediatric patients with Fanconi anemia. *Blood* 2024;144(12):1329-1342.

30. Rosenberg PS, Socié G, Alter BP, Gluckman E. Risk of head and neck squamous cell cancer and death in patients with Fanconi anemia who did and did not receive transplants. *Blood* 2005;105(1):67-73.

31. Peffault de Latour R, Porcher R, Dalle J-H, Aljurf M, Korthof ET, Svahn J, et al. Allogeneic hematopoietic stem cell transplantation in Fanconi anemia: the European group for blood and marrow transplantation experience. *Blood* 2013;122(26):4279-4286.

32. Toksoy G, Uludağ Alkaya D, Bagirova G, Avcı Ş, Aghayev A, Günes N, et al. Clinical and molecular characterization of Fanconi anemia patients in Turkey. *Mol Syndromol* 2020;11(4):183-196.

33. Shahid M, Firasat S, Satti HS, Satti TM, Ghafoor T, Sharif I, Afshan K. Screening of the FANCA gene mutational hotspots in the

Pakistani fanconi anemia patients revealed 19 sequence variations. *Congenit Anom* 2020;60(1):132-139.

34. Pilonetto DV, Pereira NF, Bonfim CM, Ribeiro LL, Bitencourt MA, Kerkhoven L, et al. A strategy for molecular diagnostics of Fanconi anemia in Brazilian patients. *Mol. genet. genomic med* 2017;5(4):360-372.

35. Castella M, Pujol R, Callén E, Trujillo JP, Casado JA, Gille H, et al. Origin, functional role, and clinical impact of Fanconi anemia FANCA mutations. *Blood* 2011;117(14):3759-3769.

36. Kimble DC, Lach FP, Gregg SQ, Donovan FX, Flynn EK, Kamat A, et al. A comprehensive approach to identification of pathogenic FANCA variants in Fanconi anemia patients and their families. *Hum. mutat* 2018;39(2):237-254.

37. Karczewski KJ, Francioli LC, Tiao G, Cummings BB, Alföldi J, Wang Q, et al. The mutational constraint spectrum quantified from variation in 141,456 humans. *Nature* 2020;581(7809):434-443.

38. Marion W, Koppe T, Chen C-C, Wang D, Frenis K, Fierstein S, et al. RUNX1 mutations mitigate quiescence to promote transformation of hematopoietic progenitors in Fanconi anemia. *Leukemia* 2023;37(8):1698-1708.

39. Moghrabi NN, Johnson MA, Yoshitomi MJ, Zhu X, Al-Dhalimy MJ, Olson SB, et al. Validation of Fanconi anemia complementation Group A assignment using molecular analysis. *GIM* 2009;11(3):183-192.

40. Quentin S, Cuccuini W, Ceccaldi R, Nibourel O, Pondarre C, Pagès M-P, et al. Myelodysplasia and leukemia of Fanconi anemia are associated with a specific pattern of genomic abnormalities that includes cryptic RUNX1/AML1 lesions. *Blood* 2011;117(15):e161-e170.

41. Nykamp K, Anderson M, Powers M, Garcia J, Herrera B, Ho YY, et al. Sherlock: a comprehensive refinement of the ACMG-AMP variant classification criteria. *Genet Med* 2017;19(10):1105-1107.